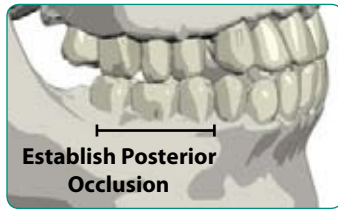


## 1 PLANNING

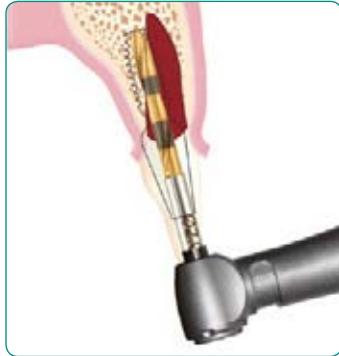
### Treatment Planning

An appropriately stable anterior and posterior occlusion is essential to avoid the possibility for the inadvertent loosening of maxillary anterior abutments.



### Surgical Planning

Since the trajectory of the pilot drill will be the long axis of the implant and its straight abutment, it should approximate the long axis of the adjacent teeth in order to minimize the use of angled abutments. Angled abutments will be more difficult to seat and therefore may lead to inadvertent loosening.



## 2 HANDLING COMPONENTS

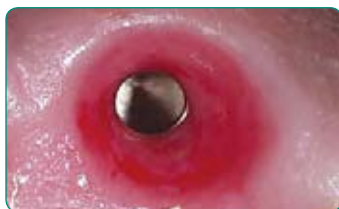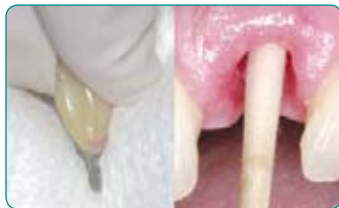### Handle Properly

Follow proper protocols when handling implant and abutment components.



### Remove Contaminants

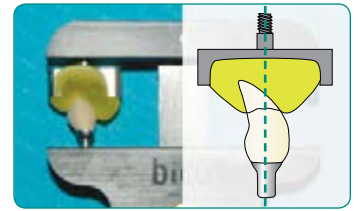
Use an alcohol wipe to effectively remove blood, glove powder, plastic detritus or other contaminants from the abutment post. Insert appropriately sized cotton-tipped applicator to clean the implant well.



## 3 PREPARATION FOR SEATING

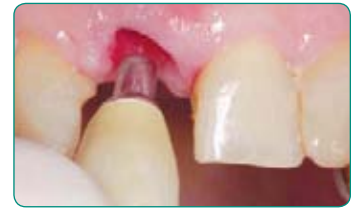### Fabricate Seating Jig

Using a Crown Alignment Device, mold hydroplastic resin around the abutment/crown and a threaded Crown Seating Tip to facilitate tapping in the long axis of the abutment post and implant well in order to properly engage their locking taper connection.



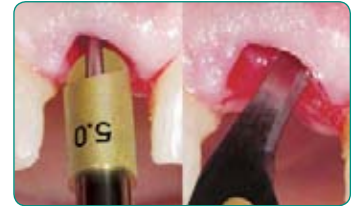### Preliminary Insertion

Seat the abutment/crown with only finger pressure for initial evaluation and removal of any interferences to its passive seating.



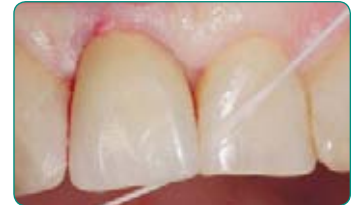### Remove Interferences

Remove any excessive interproximal tooth contact by adjusting the abutment/crown. Remove any soft tissue or bony interferences by adjusting the abutment/crown, or by relieving or removing hard or soft tissue.



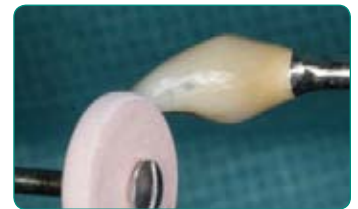### Align Abutment/Crown

Align the abutment/crown prior to confirming passive interproximal contacts with dental floss, if necessary with an incisal orientation jig. When in doubt, always adjust a contact that you think may be too tight, since non-passive interproximal contacts will inhibit the engagement of the abutment's locking taper connection.



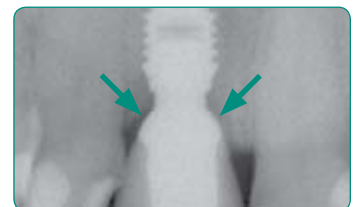
### Adjust Contacts

Adjust excessive contacts until dental floss can be passed through the contact area with only minimal resistance.



### Confirm With Radiograph

Confirm removal of bony interferences and proper seating with a radiograph.

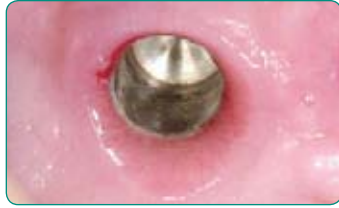

**CONTINUE TO NEXT STEPS »**

## 4 SEATING AND TAPPING

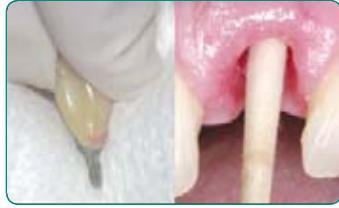### Control Bleeding

Eliminate or control bleeding by using a combination of vasoconstrictors, pressure and time.



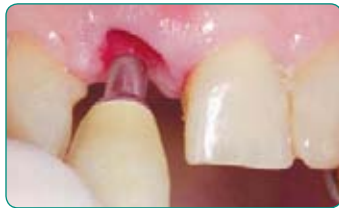### Clean Components

Clean the abutment post with an alcohol wipe and implant well with an appropriately sized cotton-tipped applicator.



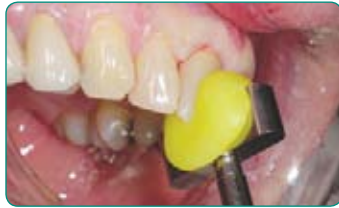### Crown Insertion

Insert and align abutment/crown using an incisal orientation jig when necessary.



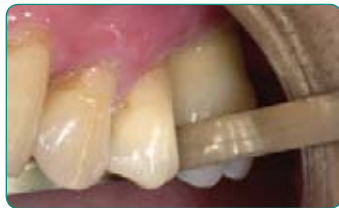### Initial Seating Tap

While digitally supporting the bridge of the patient's nose, apply an initial seating tap using a custom seating jig on a threaded straight handle to assure that the seating forces are being directed in the long axis of the implant.



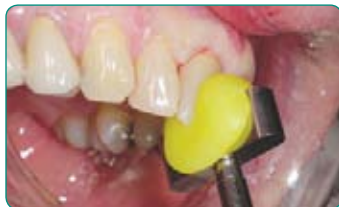### Confirm Contacts

Confirm passive interproximal contacts with dental floss and, if necessary, remove the prosthesis by tapping on the handle of a grasping forceps to adjust any non-passive interproximal contact area. Alternatively, a thin metal finishing strip may be used without having to remove the restoration.



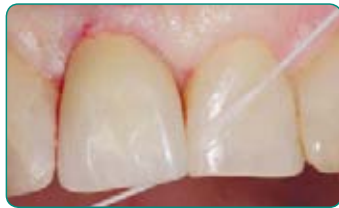### Seating Taps

After confirming passive interproximal contacts and while digitally supporting the bridge of the patient's nose, intermittently apply six additional definitive seating taps using a custom seating jig and a 250g or heavier mallet.



### Reconfirm Contacts

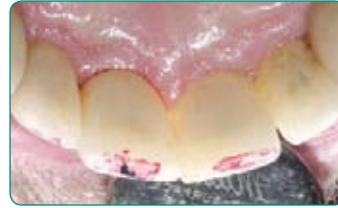Reconfirm the presence of passive interproximal contacts. If contacts are too tight, remove the crown/abutment for further adjustments.



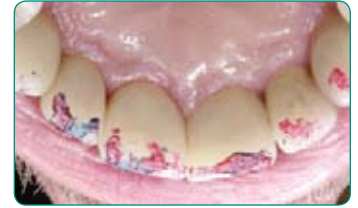## 5 EVALUATION AND ADJUSTMENT

### Check Occlusion

Establish uniform contacts initially in maximal intercuspation and then in protrusive and retrusive excursions.



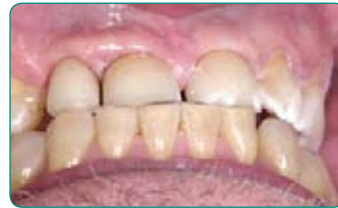Initial contacts.



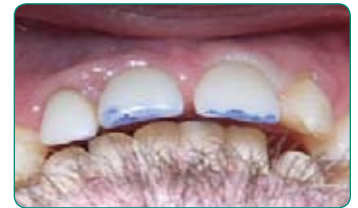Contacts after adjustments.

### Adjust Contacts **While Clenching**

Establish uniformly balanced contacts while the patient is **clenching in all extreme excursions including retrusive movements of the mandible from an extreme protrusive position**, which may indicate the need to adjust the facial aspect of the restoration.



Contact during retrusive mandibular movement.



Markings from the retrusive movement of the mandible while clenching indicate the need to reduce the facial contour of the restorations. Note that there is no contact in maximal intercuspation.

### KEYS TO SUCCESS

- Be patient while diligently following all aspects of the prescribed techniques especially with the meticulous evaluation and adjustment of the interproximal and incisal contacts.
- Assure that there is an appropriate anterior and posterior occlusion.
- Remove all soft and hard tissue interferences.
- Spend as much time as necessary with multiple adjustments to **establish passive interproximal contacts**.
- Clean abutment post and implant well with an alcohol wipe.
- Use a custom seating jig to direct seating forces in the long axis of the abutment post and implant well.
- Engage the locking taper connection with six definitive taps using a 250 gram or heavier mallet.
- After definitively seating the implant/crown, reconfirm the presence of passive interproximal contacts and, if necessary, make the appropriate adjustments.
- Patiently evaluate and meticulously adjust incisal contacts with thin marking paper while the patient is **clenching** and moving their mandible in all extreme excursions.